

See discussions, stats, and author profiles for this publication at: <https://www.researchgate.net/publication/336082456>

Prevalence of intestinal helminths infection in patients reporting to the microbiological laboratory at Tishreen University Hospital, Lattakia, Syria, during the years 2016–2017

Article in *Journal of Chemical and Pharmaceutical Sciences* · July 2019

DOI: 10.30558/jchps.20191203004

CITATIONS

0

READS

150

3 authors, including:



Kanaan Al-tameemi

Al-Arab University for Science & Technology

29 PUBLICATIONS 81 CITATIONS

[SEE PROFILE](#)



Raiaan Kabakli

Al Andalus University

15 PUBLICATIONS 44 CITATIONS

[SEE PROFILE](#)

Prevalence of intestinal helminths infection in patients reporting to the microbiological laboratory at Tishreen University Hospital, Lattakia, Syria, during the years 2016-2017

Kanaan AL-Tameemi^{1*}, Amal Dayoub², Raiaan Kabakli³

¹Department of Microbiology, Al-Andalus University for Medical Sciences, Tartous, Syria

²Department of Environmental Protection, Tishreen University, Lattakia, Syria

³Department of Basic Sciences, Al-Andalus University for Medical Sciences, Tartous, Syria

*Corresponding author: E-Mail: d_knaan@yahoo.com

ABSTRACT

The study was conducted with the aim of detecting intestinal helminth infection in those living in Lattakia Governorate, and to determine their species and prevalence through laboratory screening of stool samples for patients visiting the Microbiology Laboratory at Tishreen University Hospital - Lattakia during the years 2016 - 2017.

By investigating the presence of eggs in the stool samples, the results of the laboratory tests conducted on the stool samples showed a prevalence of helminth infection in the intestinal tract in the population of Lattakia. Seven species of intestinal parasitic worms were recorded due to the patients examined: 3 Species of Nematoda (*Enterobius vermicularis*, *Ascaris lumbricoides*, and *Ancylostoma duodenale*), and 4 Species of Plathelminthes: two species belong to the class Trematoda: Class: *Paragonimus Westermani* and *Schistosoma mansoni*, and two cases belonging to the class Cestoda: *Hymenolepis nana*. This study has recorded, for the first time, the infection with *Ancylostoma duodenale* and *Schistosoma Mansoni* in Syria.

The overall prevalence of intestinal helminth infection was reported in patients who were referred to the Microbiology laboratory in Lattakia during the years 2016- 2017 was 3.77%. The vast majority of those infected with only one species of intestinal worms, while registered two cases of infection multiplier: *Ascaris lumbricoides* and *Enterobius Vermicularis*.

The study showed that *Enterobius Vermicularis* is the most common intestinal worms in the population in Lattakia (13.2%), followed by the *Ascaris lumbricoides*, then the stalagmites. The prevalence of intestinal helminth infection in Lattakia was higher among males than females, and prevalence of intestinal helminthiasis was highest in winter and autumn of 2016-2017.

KEY WORDS: Intestinal parasitic worms, patients reviewed, microbiological laboratory, Tishreen Hospital.

1. INTRODUCTION

Intestinal parasitic diseases spread throughout the world, and constitute a high prevalence in economically and socially disadvantaged communities in tropical and subtropical regions. This is likely due to poor sanitation and inadequate hygiene (Allen, 2017; Latha, 2010).

It is estimated that more than 60% of the world's population is infected with intestinal parasites, which may play a role in pathological disorders that agree with intestinal infections, about 3.5 billion people with intestinal parasites, 450 million children are infected as a result of these infections. Amebiasis, Ascariasis, Hook worm, and Trichuriasis are among the 10 most common diseases in the world. These diseases spread to become a global health problem, especially among children in poor communities in developing countries. The epidemiological assessment of these diseases usually depends on the number of infections (Prevalence) in the world, because the clinical symptoms of these diseases are very mild (Hotez, 2009).

Intestinal parasites, whether they are *Entamoeba histolytica*, *Giardia lamblia*, or *Ascaris lumbricoides* and *Taenia sp.* one of the most prevalent intestinal parasites worldwide. More than a third of the world's population is infected with soil-transmitted Helminthes (STH) mainly in developing countries in Asia, Africa and Latin America. Land-borne worms are parasitic worms that cause disease to humans. *Ascaris lumbricoides* are the most common soil-borne worms, with estimated 1 billion lesions. *Trichuris trichiura*, (hook worms) *Necator americanus* and *Ancylostoma duodenale* each makes up approximately between 600 and 800 million cases (World Health Organization, 1998).

The medical and health importance of infection of intestinal worms is widespread in the world and affects a wide range of the population, due to the easy infection in most of the species. Infection with worms such as *Ascaris lumbricoides* and *Trichuris trichiura* and barcodes such as *Hymenolepis nana* easily occur by eating eggs with vegetables and water contaminated with sewage waste, as in many regions of the world (Cruz, 2015).

The geopolitical, demographic, economic and social characteristics of third world countries have a significant impact on the survival of parasitic diseases on the list of unresolved health problems. Climate and environmental conditions such as high temperatures, increased humidity, social and economic conditions such as poverty, illiteracy, poor health services, poor hygiene, lack of water security, lack of access to potable water, etc.

play a major role in the high incidence of intestinal parasites, reduce the chance of combating them and eliminate the diseases (Dash, 2010; Erismann, 2016; Kang, 1998).

The pathogenic effects of intestinal worms are: toxic effects by enzymes and metabolites and other spoliation as a result of feeding the worms on the blood of the thaw, such as forceps, absorption of vitamins, and adverse effects such as blockage of the intestines and impede digestion. These effects appear in the form of gastrointestinal symptoms (vomiting, nausea, abdominal tingling, diarrhea, constipation), appetite disorder (increase or decrease) and sensory, motor, psychological and sensory neurological symptoms (Drake, 2000; Davis, 2002; Thielman, 2004; Al-Shammari, 2001).

Numerous studies have been conducted on the prevalence of intestinal helminth infections in the population globally and regionally (Al-Shammari, 2001).

In Syria, the study of the species of intestinal parasites and their prevalence in humans has been going on since 1989. The study was conducted in different regions of the country, including the study of Ebrahim (2004), in Homs, AL-kofari and Ismail (2008), in Damascus and its countryside, and the study of AL-kofari, Harba (2009) in Idlib governorate and its countryside, Harba (2009), study Mohammed (2010), the first in the countryside of the province of Daraa, and the second in the region of Kalamoun - Damascus countryside, in 2014, AL-habbal (2014), studied the spread of intestinal parasites in individuals living in the region of Kalamoun in Syria, and a first-time study in the province of Lattakia on the role of intestinal parasites in digestive gastrointestinal disorders involved the identification of types of intestinal worms and their prevalence in a segment of the population of Lattakia Governorate.

2. MATERIALS AND METHODS

The stool samples were examined in the microbiology laboratory at Tishreen University Hospital, Lattakia during the years 2016 - 2017.

The direct method was applied in examining the faecal samples. At least three tests were conducted for each sample. The examination included the following:

Examination of the faeces: in order to determine the strength (fluid / solid), the color of the stool and its Viscosity and homogeneity, as well as in the presence of pus, mucus or addicted.

Microscopy of stool samples: The microscopy was conducted directly without coloring, and with coloring using the solution of iodine. A drop of the physiological serum was placed on a glass slide at one end, and on the other was a drop of the iodine solution (1, A) (allowing the coloring of intestinal worms and showing some structures and structural formalities), then mixed homogeneously in the physiological serum and logol solution, covered with a glass microscope (Fig.1).




Figure.1. Direct examination of faeces in a wet swab method using physiological serum and logol solution.

In addition, we used the technique of precipitation (Formalin - Ethyl Acetate Technique) by using the trap. This technique enables us to detect the parasites in as little impurities as possible using physiological solution, formalin 10%, Ethyl acetate and 10 minutes 2000 cycle / minute method. (Garcia, 1997; World Health Organization, 2008) and then colored preparations in the logol for the resulting sediment were prepared and examined under the microscope at magnification $40 \times 100 \times$.

Depending on the shape and dimensions, the diagnosis of intestinal worms by detecting their eggs in the faeces and determining them was adopted. (Haghighi, 2009; Al-Hindi, 2009).

3. RESULTS AND DISCUSSION

Identifying the types of parasitic intestinal parasites of the population in Lattakia: The laboratory examination of stool samples have shown the prevalence of intestinal helminth infection in the population in Lattakia through the presence of eggs in the stool this was done after isolating the samples and studying their morphological characteristics and microscopic dimensions, and their compatibility with global studies and research (World Health Organization, 2004).

It was found that the samples contain 7 types of intestinal helminths, 3 types of Nematoda *Enterobius vermicularis*, *Ascaris lumbricoides*, Hook worm (*Ancylostoma duodenale*), 4 types of flat worms (Plathelminthes):

Two types belonging to the class of Trematoda are: *Paragonimus westermani* and the *schistosoma mansoni*, and two types of barcodes Class: Cestoda is the *Hymenolepis nana*.

Here we review the morphological and micrometric parameters of the isolated intestinal helminth eggs identified in our study.

Nematoda: Three types of eggs were recorded for three different types of worms:

***Enterobius vermicularis*:** Although the diagnosis of this worm depends mainly on the method of cellophane, and rarely would the eggs or worms in the adult stool be seen, we have been able to notice more than once to see the eggs of this worm in the stool and once recorded the presence of female worm when filled with eggs was recorded, Figure (2, A, and B). The eggs of the worm were characterized by their convex, asymmetrical, oval shape on one end more than on the other, transparent, measuring 56.07 microns in length and 25.43 microns in width, consisting of a double transparent crust (Fig.2).

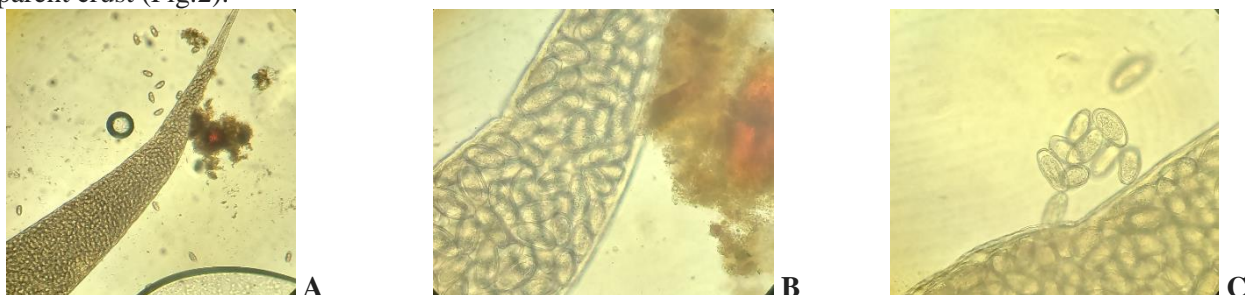


Figure.2. Female Serpentine with eggs inside (A, B, C) magnifications 4×, 10×

***Ascaris lumbricoides*:** This worm is known as the abdominal long because it is the longest intestinal catheter, caused by the so-called Ascariasis. We have identified two types of fertilized and unfertilized eggs in the feces where the fertilized eggs are almost spherical in color, brown, the eggshell is equipped with inflorescences of ornamentation or protruding protrusions, a distinct embryonic mass of 55-75 x 35-50 μm, and non-fertilized eggs larger, slightly oval, less distinctive and sometimes with non-existent decorations, the embryonic mass is unclear (Fig.3).




Figure.3. Ascaris eggs, A: non-fertilized eggs, B: fertilized eggs 40×

***Ancylostoma duodenale*:** Hookworm, also known as the hookworm, is a dangerous intestinal tract where it feeds on the blood and remains, associated with the intestinal mucosa through its oral cavities to absorb blood and interstitial fluid. The eggs of the worm were easily identified by their distinctive shape, oval-shaped with a thin transparent crust. A fetal mass was observed in the center of the egg (figure.4)

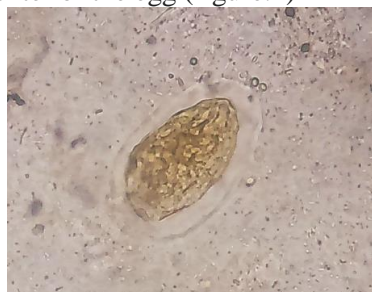

Figure.4. *Ancylostoma duodenale*. Egg 40×

Types of flatworms Plathelminthes: 4 species belonging to two different classes, two species belong to the row of ribbons, and two species belonging to the class of penalties:

Row of barges: Cestoda:

Type of dwarf species *Hymenolepis nana*: The eggs of this worm were easily distinguished by their unique, colorless shape, measuring 35-45 microns, with two outer and inner casing between them. There are two symmetrical protrusions of 4 - 8 cilia. The egg contains a hexacanthus embryo (Onchosphere) (figure.5).

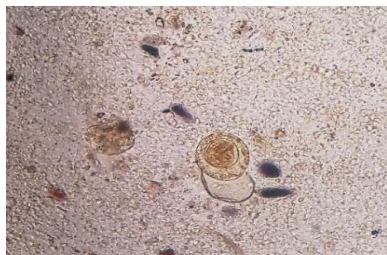


Figure.5. *Hymenolepis nana* dwarf egg 10×, 40×

***Taenia saginata*:** The case of an infected child has been reported by the mother of a 13-year-old girl whose daughter suffers from wasting, anemia, and lack of growth. Clinical symptoms that the child is aware of occasionally trigger an occasional tickling of small white worms outside of defecation. That the girl had received treatment for the infection of intestinal worms without a stool test did not lead to healing or improve the health of the girl. The mother was asked to bring a sample of worms inserted in a sterile plastic container with a minimum of 70% alcohol.

At the time of the test, by using the magnifying glass and the microscope, they were identified as gravid segments of the tapeworm (*Taenia saginata*). The dimensions of the pieces were observed. The rectangular openings on the sides of the pieces were shown in Fig.6A. The average length of the piece was 0.8 x 0.5 cm, the average diameter of the eggs was 30.6 microns, and after taking the measurements for the pieces and the eggs, the pieces were sent to the anatomy laboratory Patients at Tishreen Hospital to conduct histological sections sure diagnosis.

A microscopic examination of the tissue sections of the cut showed the observation of the uterine branches within the segment, and the spherical egg-shaped agglomerate with the densely shaped, hexacanthus embryo (6, C, D).

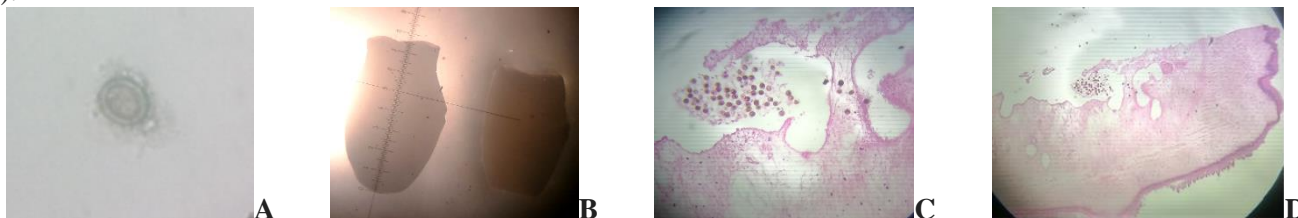


Figure.6. A: The gravid segments of *Taenia saginata*, B: egg 40 ×, C, D:

A section of tissue in the gravid segment and the concentrations of eggs in the center 20 ×

Trematoda: Two different types of eggs belonging to two types of worms were identified: 1 - *Schistosoma mansoni*: We could distinguish the eggs of this worm microscopically through the shape and size of the distinctive egg and the presence of lateral side fork, which is an important diagnostic component of this egg. *Schistosoma mansoni* was large, oval in color, brown to golden, with a smooth translucent cover with a long, clear side fork. The eggs ranged between 114-175 x 45-70 micrometers. Figure.7.



Figure.7. *Schistosoma mansoni* eggs 40 ×

Schistosoma mansoni is one of the most dangerous parasites in human life and is second only to malaria. *Schistosoma mansoni*, a mesenteric blood vessel, is one of the flatworms belonging to a separate species of sex. It feeds on blood, causing human schistosomiasis.

***Paragonimus westermani*:** This species belongs to the female genital herpes, which affects the lungs, and its eggs are exposed with the eucalyptus and feces. We could see its eggs in the feces, which appeared oval, large in size, 80-120 x 45-70 μm in color, brown, thick egg crust. Figure.8.

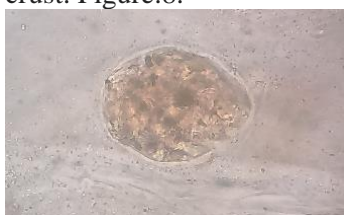

Figure.8. *Paragonimus westermani*, egg 40×

While reviewing the results, we noticed that the number of isolated intestinal helminth isolates was higher in 2017 than 2016, and this foreshadows the deterioration of the health situation as a result of the continued war in the country and the weakness of services (Table.1).

Table.1. Diversity of intestinal worms recorded in 2016 - 2017.

Year	Species number of intestinal parasites recorded	Species of intestinal parasites recorded
2016	4	<i>Enterobius vermicularis</i> <i>Ascaris lumbricoides</i> <i>Ancylostoma duodenale</i> <i>Schistosoma mansoni</i>
2017	6	<i>Enterobius vermicularis</i> <i>Ascaris lumbricoides</i> <i>Ancylostoma duodenale</i> <i>Hymenolepis nana</i> <i>Taenia saginata</i> <i>Paragonimus westermani</i>

Based on the results of previous local studies conducted in several Syrian areas, it was found that the incidence of spastic force was first recorded in Syria in this study.

Determining the prevalence of infection and parasitic intestinal parasites isolated and changes during the seasons: The number of referred patients of the microbiology laboratory to conduct a stool test during 2016, 2017: 610, 90% of them were children between the ages of 3-12 years of paediatric clinics and outpatients, in addition to few stool samples from women's clinics, glands and digestive tract. The number of infected intestinal helminths was 27 patients with a prevalence rate of 3.77%. The vast majority of patients had only one species of intestinal helminth, while two cases of infection were reported with the presence of worms (*Ascaris lumbricoides* and *Enterobius Vermicularis*), the second with worms (*Ancylostoma duodenale* and *Paragonimus Westermani*). Syria is involved in military operations.

In Table.1, *Enterobius Vermicularis* were the most prevalent intestinal worms in the population of Lattakia (2.13%), followed by the *Ascaris lumbricoides* and then *Ancylostoma duodenale*, in contrast to the results of the previous local studies presented in Syria (World Health Organization, 2004), *Ascaris lumbricoides* was one of the most common worms, and prevalence was higher than that recorded in the study with the results of many previous studies conducted in Syria.

Table.2. Prevalence of intestinal helminths infection in patients visiting microbiological laboratory at Tishreen University Hospital in Lattakia and its changes by sex during 2016-2017

Year	Total number of referred patients for stool exam	Number of infected referred according to the species of parasite						
		<i>E. vermicularis</i>	<i>Ascaris lumbricoides</i>	<i>Ancylostoma duodenale</i>	<i>H. nana</i>	<i>T. saginata</i>	<i>Sch. mansoni</i>	<i>p. westermani</i>
2016	17/197	10	3	4	-	-	1	-
2017	6/413	3	2	1	1	1		1
Sum	610	13	5	5	1	1	1	1
Prevalence rate%		2.13	0.82	0.82	0.16	0.16	0.16	0.16

Year	Number of infected referred with helminths according to gender		Number of referred patients for stool exam according to gender	
	Male	Female	Male	Female
2016	11	5	131	66
2017	4	3	245	168
Sum	15	8	376	234
Prevalence rate%	3.99	1.31		

The study also showed that the incidence of intestinal helminth infection in Lattakia was higher among males than in females. The percentage of infection in males was 3.99% and that of females was 1.31%. The results were consistent with many local and international studies (Stephenson, 2000).

The researchers also confirmed that *Ascaris lumbricoides* and *Ancylostoma duodenale* transmitted through the soil are among the most common intestinal worms that inhabit human intestines. The *Enterobius Vermicularis* is among the most prevalent in the world, with 30% of the world's children suffering from scorching.

As for the seasonal changes of intestinal helminth infection in the population in Lattakia, Table.3.

Table.3. Quarterly changes in intestinal helminth infection in the population in Lattakia during the years 2016-2017

Year	Season	Number of referred patients for stool exam	Number of infected persons with helminths	Infection rate %
2016	Winter	33	4	12.12
	Spring	54	3	5.56
	Summer	68	4	5.88
	Autumn	42	6	14.29
Sum		197	17	8.63
2017	Winter	60	4	6.67
	Spring	114	1	0.88
	Summer	147	-	-
	Autumn	92	2	2.17
Sum		413	7	1.69

The prevalence of intestinal helminths was highest during the winter and autumn of 2016 and 2017. This may be due to seasonal food. People eat fresh vegetables such as lettuce, parsley and cabbage in addition to the rainy season, which contributes to the transmission of the pathogens and spread them in the environment, and some researchers have confirmed that temperatures and humidity play a greater role in the development of forms and stages of infectious intestinal parasites.

The study also showed that the incidence of intestinal helminth infections in Lattakia was higher in 2016 than in 2017. This may be due to the poor social, economic and health conditions in the various regions due to the current security situation in the country and its decline and improvement of economic and social conditions in 2017. In 2016. However, the burden of intestinal diseases can be reduced through support and provision of health awareness programs in health centers accredited in different residential areas in parallel with schools that are highly competent in terms of Cost and capability.

As this group is responsible for maintaining the infection of intestinal parasites and spreading them in the community. Insufficient access to basic health services such as clean water, provision of health services, etc., improvement of economic and social conditions, and health safety tools in occupations associated with the possibility of intestinal parasitic worms.

Most studies (Stephenson, 2000) have shown that intestinal worms rarely cause death to humans. Instead, disease burden is associated with a lower mortality rate than acute and chronic effects on the health and nutritional status of the host. The infection of intestinal worms weakens the mental and physical development of children, the decline of cultural level, and the disruption of economic development.

4. CONCLUSIONS AND RECOMMENDATIONS

Registering 7 types of intestinal helminth worms in patients who were referred to the Microbiology Laboratory at Tishreen University Hospital in Lattakia. - The general prevalence of infection of intestinal parasitic worms in patients visiting microbiology laboratory at Tishreen University Hospital was 3.77%. The *Enterobius Vermicularis* were one of the most common intestinal worms in Lattakia Governorate (2.13%), followed by *Ascaris lumbricoides*.

The study showed that the prevalence of infection of parasitic intestinal parasites in the province of Latakia was higher in males than in females. - The highest prevalence of infection of intestinal parasitic worms in the province of Lattakia was in the winter and autumn of the years 2016 and 2017.

REFERENCES

- AL- Kofari A, Harba A, Intestinal parasites in children of essential education in Idlib city and its countries, Laboratory diagnostic journal, 5 (2), 2009, 37-46.
- AL-Habbal A, Prevalence Of Intestinal Parasites in Alqalamoun Region in Syria, Journal of Al-bass University, 36 (3), 2014, 20.
- Al-Hindi A, Diagnosis of gastrointestinal parasites among hospitalized patients attending Al-Nasser Paediatric Hospital, Gaza, Palestine, J Public Health, 17, 2009, 49-53.

AL-Kofari A and Ismail M.T, The massive delegation of human intestinal parasites especially helminthes in Damascus and its country sides, A diagnostic study, between the period 1998-2007, Journal of laboratory diagnosis, 2008.

Allen R, keren P, Catubig L, Chau, Thao R.N, Marianne I, Shu – koy T, Poverty NG, Dietary intake, Intestinal Parasites and Nutritional status among school-age children in the rural Philippines, Tropical Medicine and infectious Diseases, 2, 2017, 10-49.

Al-Shammari S, Khoja T, El-Khwasky F, Gad A, Intestinal parasitic diseases in Riyadh, Saudi Arabia, prevalence, sociodemographic and environmental associates, Tropical Medicine & International Health, 6, 2001, 184-189.

Bethony J, Brooker S, Albonico M, Geiger S.M, Loukas A, Diemert D, Hotez P.J, Soil-transmitted helminth infections, Ascariasis, trichuriasis and hookworm, Lancet, 367, 2006, 1521-1532.

Caccio S.M, DE Giacomma M, Aulicino F.M and Pozio E, Giardia cysts in waste water treatment plants in Italy, Applied environmental microbiology, 69, 2003, 3393-3398.

CDC DPDx, Laboratory Identification of Parasites of Public Health Concern, Atlanta, Center for Disease Control and Prevention, USA, 2009.

Cruz Ch.P, Abu Bakr S.A, Abdullah J.C.A.A, Alabdan M.A, Prevalence of Intestinal Parasites in Afif, Saudi Arabia, A5-Year Restrospective Study, International Journal of Current Microbiology and Applied Sciences, 4 (5), 2015, 746-751.

Dash N, Al-Zarouni M, Anwar KH and Panigrahi D, Prevalence of Intestinal Parasitic Infections in Sharjah, United Arab Emirates, Human Parasitic Diseases, 2, 2010, 21-24.

Davis AN, Haque R, Petri WA, Jr. Update on protozoan parasites of the intestine, Curr Opin Gastroentrol, 18, 2002, 4-10.

Drake LJ, Jukes MCH, Sternberg RJ, Bunday DAP, Geohelminth infections (ascariasis, trichiuriasis and hookworm), cognitive and development impacts, Sem Paediatr Infect Dis., 11, 2000, 245-251.

Ebrahim G, Iron deficiency and zinc in the serum of children infected with Giardia lamblia in HOMS, SYRIA, Phd thesis, Supervised by Dr. Mohamed Taher Ismail, Faculty of medicine, Damascus University, 2004.

Erismann S, Diaghougua S, Odematt P, Knoblauch A.M, Gerold J, Shrestha A, Grissoum T, Kabore A, Schindler CH, Utzinger J, Cisse G, Prevalence of intestinal parasitic infections and associated risk factors among schoolchildren in Plateau Central and Centre - Ouest regions of Burkina Faso, Parasitic and Vectors, 9554, 2016, 14.

Garcia I.S and Bruckner D.A, Diagnostic Medical parasitology 3 rded, A.S.M. Press Washington .D.C., 1997.

Haghighi A, Khorashad S, Mojarad N, Kazemi B, Nejad R, Rasti S, Frequency of enteric protozoan parasites among patients with gastrointestinal complaints in medical centers of Zahedan, Trans R Soc Trop Med Hyg., 103, 2009, 452-454.

Harba A, Intestinal parasites infection in children of essential education level in Damascus city and its countries, Higher studies thesis, Supervised by Dr. Mohammed Taher Ismail, Faculty of medicine, Damascus University, 2009.

Hotez P.J, Mass drug administration and integrated control for the world's high-prevalence neglected tropical diseases, Clin. Pharmacol. Ther., 85, 2009, 659-664.

Ismail M.T, Musily M, AL- ZIB S, AL- Halak N, Shafa R, Bibors B, and AL- Maleh M, Intesinal parasites prevalence in children of essential education level in Daraa city / Syria, Arabic Journal for Pharmacy Sciences, 2010.

Kang G.M.D, Prasana R.D, Jasper D.D, Minnie M, Mathan M, Mathan VI and Muliyl J.P, Prevalence of intestinal parasites in rural Southern Indians, Tropical Medicine and International Health, 3 (1), 1998, 70-75.

Latha R, Senthil K, Ramadass, Nagaraji S, Muruganandam N, Karthikeyan R, Helminthes infections in school children in puducherry, South India , Journal of microbiology, Immunology and Infection, 43 (3), 2010, 228-232.

Mohammed M.AL, Amro A, Mohammed F.S, Mohammed N.AL, Abeer AL, Mohammed T.I, Intesinal parasites species prevalenc in children of essential education level in Al-Kalamon area, Damascus country, Syria, Arabic journal for Pharmacy sciences, 2010.

Stephenson LS, Latham MC, Ottesen EA, Malnutrition and parasitic helminth infections, Parasitology, 121, 2000, S23-38.

Stoltzfus RJ, Chway HM, Montresor A, Tielsch JM, Jape JK, Albonico M, Low dose daily supplementation improves iron status and appetite but not anemia, whereas quarterly anthelmintic treatment improves growth, appetite and anemia in Zanzibari preschool children, *J Nutr.*, 134, 2004, 348-356.

Thielman N.M and Guerrant R.L, Acute infectious diarrhea, *N Engl J Med.*, 2004, 338-350.

World Health Organization, Control of Tropical Diseases, Geneva, Switzerland, WHO, 1998.

World Health Organization, Facts and Figures: Water Sanitation and Hygiene Links, Water Sanitation & Health, 2008.

World Health Organization, Training manual on diagnosis of intestinal parasites, WHO/CID/SIP/98.2 CD-ROM, GENEVA, 2004.