

## A SIMPLE RETRIEVAL TECHNIQUE FOR ACCIDENTALLY DISPLACED MANDIBULAR THIRD MOLARS: A LITERATURE REVIEW

Elias Boutros<sup>1</sup>, Mohammed Sabe AlArab<sup>2</sup>, Ali N. Harba<sup>3</sup>, Fawaz Jabber<sup>4</sup>, Beshar Harfoush<sup>5</sup>, Hussam Tannous<sup>6</sup>

1. PhD in Oral and Maxillofacial Surgery, Faculty of Dentistry, Al-Andalus University, Qadmous, Syria

2. Prof, PhD in Oral and Maxillofacial Surgery, Faculty of Dentistry, Hama University, Hama, Syria

3. MSc student, Oral and Maxillofacial Surgery, Faculty of Dentistry, Tishreen University, Lattakia, Syria

4. Master in Oral and Maxillofacial Surgery, Faculty of Dentistry, Hama University, Hama, Syria

5. Student, Department of Oral and Maxillofacial Surgery, Faculty of Dentistry, Al-Andalus University, Qadmous, Syria

6. Student, Department of Oral and Maxillofacial Surgery, Faculty of Dentistry, Al-Andalus University, Qadmous, Syria

### ABSTRACT:

**Purpose:** To review the literature associated with displaced lower third molars, to review the methods of retrieval an accidentally displaced lower third molar tooth.

**Materials and Methods:** A review of the literature was performed to record the types of displacements, patient's personal data, imaging used, and the surgical approaches with their complications .

**Results:** thirty two articles were identified and reviewed. There were no gender differences and the third and fourth decades of life were the most common time for this mishap to occur. lower third molars were displaced into 6 different tissue spaces. Different methods of recovery were used.

**Conclusion:** The displaced lower third molar is a rare but potentially serious complication of extraction. Because of differences in the direction of displacement, the size of fragment, delay in retrieval, and tissue reactions, no one technique is uniformly applicable. When the accident occurs, the general dentist should refer the patient to an oral and maxillofacial surgeon as soon as possible. The surgeon should localize the fragment by appropriate imaging and should remove it by a technique suited to the situation.

**Key-words:** accidentally displaced mandibular third molar, pterygomandibular space, sublingual space, pharyngeal space, displaced in soft tissue.



### INTRODUCTION

The accidental displacement of a lower third molar or one of its root fragments is not common during extraction, but is nevertheless a well-recognized complication that is frequently mentioned in textbooks<sup>[1]</sup>. Accidental displacement of some portion of the lower third molar into the sublingual, submandibular, or pterygomandibular space is a rare complication<sup>[2]</sup>.

Because the incidence of third molar displacement is very low, there are only a few case reports of this condition in the literature and there is little information about it in general<sup>[2]</sup>. The aim of this article is to review the literature, to review the methods of retrieval an accidentally displaced lower third molar tooth, to recommend rational guidelines for management of

the displaced mandibular third molar tooth or root fragment.

## **MATERIALS AND METHODS:**

Using a PubMed literature search, we identified and reviewed papers using these key words: accidentally displaced mandibular third molar, pterygomandibular space, sublingual space, pharyngeal space, displaced in soft tissue.

Papers were retrieved from 1958 to 2016 and we recorded the case number, age, gender, direction of displacement, complications, time from displacement to retrieval, surgical approach, and complications of retrieval. Papers in English were reviewed

## **RESULT:**

Of 32 papers published on this topic between 1958 and 2016, we were able to retrieve and interpret all of them (Table 1). There were no gender differences and the third and fourth decades of life were the most common time for this mishap to occur. Lower third molars were displaced into 6 different tissue spaces. Different methods of recovery were used.

## **DISCUSSION:**

Accidental displacement is a rarely reported during the surgical removal of impacted molars. Unfortunately, there is no sure way of predicting such a transoperative accident, even following thorough review of past medical history and radiographic examination<sup>[34]</sup>.

Displaced fragments may vary in size and may appear in different tissue spaces. The delay time between displacement and retrieval varies widely. Consequently, no single method of retrieval is applicable to all circumstances<sup>[13]</sup>.

The timing of the retrieval attempt has been the subject of some debate. Huang and colleagues<sup>[1]</sup> favor as early an attempt at retrieval as possible. Some authors prefer to postpone the surgery for several weeks to allow fibrosis to occur and thereby stabilize the tooth in a firm position<sup>[13]</sup>.

In Huang and colleagues<sup>1</sup> review they found that when there was a delay in referral of more than 24 hours the result was more pain, more swelling, and trismus. Furthermore, some reports document infection<sup>[10,11-13]</sup> and migration<sup>[13,15]</sup>..

The localization of a mandibular third molar requires posteroanterior, occlusal, submentovertex and panoramic views. A CT scan is used to localize a tooth/fragment when it is deemed to be in deeper tissues spaces like the lateral pharyngeal or deep cervical space<sup>1</sup>. Anand and Patil<sup>[27]</sup> prefer to use the preliminary radiographs brought by the patients, if any, only for confirmation of the diagnosis of tooth displacement. They routinely use a CT scan with a three-dimensional image reconstruction to precisely locate the tooth in three-dimensional spaces so as to aid in planning the surgical approach needed in

each case. The CT scan is performed as close to the time of operation as possible as the position of the tooth can change with time. The use of CT or cone beam CT should be the preferred imaging modality whenever they are available<sup>[27]</sup>.

Huang and colleagues<sup>[22]</sup> advised that the localization with images and proper surgical methods were the keys to retrieving the displaced fragment successfully. When immediate retrieval was decided on, Panorex and occlusal view were useful in localizing the displaced fragment. When the fragment moves into a deeper space or the retrieval has been delayed for months, three-dimensional CT seems to be a better choice.

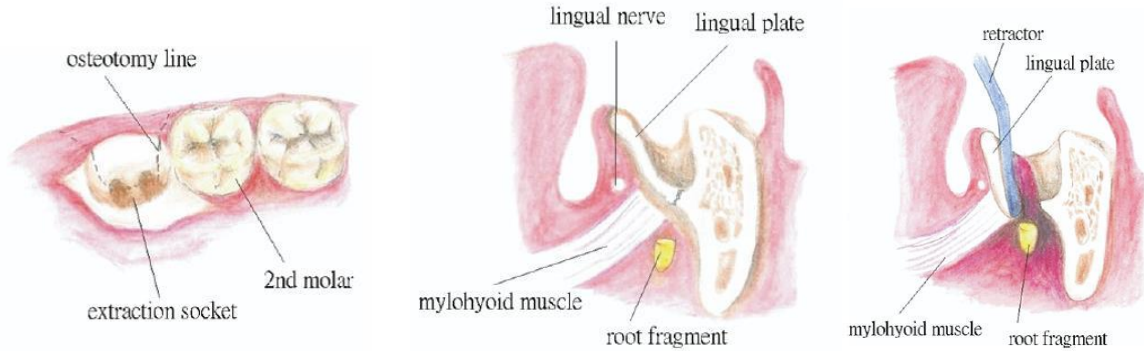
Jolly and colleagues<sup>[2]</sup> reported If a dental fragment becomes displaced into a deep space, it is very important to determine the exact location by CT or high-quality radiography. An experienced surgeon should be consulted to avoid any inadvertent complications.

Mandibular third molars may be displaced into the sublingual, submandibular, pterygomandibular and lateral pharyngeal spaces. Lower third molars that are pushed through a perforation in the thin lingual plate normally pass inferiorly to the mylohyoid muscle<sup>[35]</sup>. It is recommended that the operator place his or her thumb underneath the lower border of the

mandible in an attempt to direct the tooth back along the lingual surface of the mandible. In some cases, the fragment will be palpable<sup>[27]</sup>.

In 1958, Howe<sup>[3]</sup> reported removal of a complete mandibular third molar from the floor of the mouth. Stacy and Orth<sup>[4]</sup> described the removal of a third molar root fragment from a similar site in 1964. Some reports focused on localization using computed tomography (CT) scans<sup>[13,14,19,21]</sup> while others described the surgical retrieval in detail<sup>[12,18]</sup>. Intraoral, extraoral, and combined procedures have been used. An extended lingual mucoperiosteal flap extending from the ramus to (at least) the premolar region may be regarded as the "conventional method" of retrieval<sup>[10,21]</sup>.

If the fragment is small and close to the socket, Huang and colleagues<sup>[1]</sup> suggest that their modified method is very suitable. When the fragment is large and palpable, one may use either the modified method or the conventional method, with pressure upwards from beneath the mandible if needed. Huang and colleagues<sup>[1]</sup> described a 'modified method', an osteotomised lingual plate flap in which the bony segment remains attached to the periosteum and can be replaced into its original position (FIGURE 1). Huang and colleagues<sup>[1]</sup> suggested that modified method appears to save time and have few complications.



**Figure 1.** modified retrieval surgery for displaced right mandibular third molar. osteotomy of lingual plate of the socket. retraction of the lingual plate with soft tissue attachment lingually to expose the fragment(Huang, Wu, and Worthington. Accidentally Displaced Lower Third Molar. J Oral Maxillofac Surg 2007)

Yeh<sup>[18]</sup> described a combined intraoral and lateral neck approach in which the original wound is extended lingually to the distal of the first molar. This is combined with a 4 mm skin incision made in the submandibular region. A haemostat is then inserted along the lingual surface of the mandible to stabilize the tooth while the surgeon palpates the tooth with an index finger. A Kelly clamp can be inserted to deliver the tooth upward into the mouth. This method is believed to limit further displacement of the tooth and limits the length of lingual flap reflection necessary. This method may be used when the fragment is large and distant from the socket<sup>[18]</sup>.

To remove the lingual plate and cut the mylohyoid muscle, described by Stacy and Orth<sup>[4]</sup>, is usually not necessary. It cannot be understated that careful retraction of the lingual flap preferably by a trained assistant is of paramount importance during the retrieval surgery. Some authors recommend identifying and protecting the nerve<sup>[17]</sup>.

Extraoral and combined extraoral/intraoral approaches have been described <sup>[11,13,18]</sup>. This may be needed if the fragment is large and distant from the socket, as described by Yeh<sup>[18]</sup>.

Gay-Escoda and colleagues<sup>[11]</sup> reported a case in which the displaced tooth was retrieved via a transcutaneous approach as the tooth was located between the sternocleidomastoid and the platysma muscles as a result of progressive exteriorisation due to a prolonged inflammatory reaction. Esen and colleagues<sup>[13]</sup> described a case in which a mandibular third molar was removed transorally from the tonsillar fossa through a vertical incision from the tonsillar fossa to the retromolar trigone after completion of a tonsillectomy

## CONCLUSION:

The suggested course of action in such situations is outlined by Anand and Patil<sup>[27]</sup> :

- 1) Patient should be promptly informed about the accident and the possible treatment options should be fully discussed.
- 2) In the event, the professional is not experienced and skilled enough to perform the retrieval surgery, and/or the patient is not in physical and/or psychological conditions to support the surgical intervention within the same session, surgery is postponed to a next date when the patient feels more comfortable. Referral to a skilful oral-maxillofacial surgeon is the conduct of choice. In the meantime, between the first and second interventions, the patient must be under antibiotic, analgesic and anti-inflammatory medication.
- 3) Where there has been a delay in the referral, one should note any existing nerve injury or infection, and record this carefully.
- 4) The maxillofacial surgeon should localize the tooth/ root radiographically in at least two planes or ideally with a computed tomography (CT) scan or cone beam CT and at the earliest plan the proper surgical approach necessary to retrieve the fragment.
- 5) In case the fragment is small (1/3rd of the root length or less) and has no symptoms/ complications associated with it, the maxillofacial surgeon may choose to leave it in place.

## REFERENCES:

1. Huang, I.Y., Wu, C.W., Worthington, P., 2007. The displaced lower third molar: a literature review and suggestions for management. *J. Oral Maxillofac. Surg.* 65, 1186–1190.
2. Jolly, S.S. et al. 2014. Intraoral management of displaced root into submandibular space under local anaesthesia –A case report and review of literature. *The Saudi Dental Journal.* 26, 181–184.
3. Howe GL: Tooth removed from the lingual pouch. *Br Dent J* 104:283, 1958.
4. Stacy GC, Orth D: Perforation of the lingual alveolar plate in association with mandibular third molars. Report of a case. *Oral Surg Oral Med Oral Pathol* 17:586, 1964.
5. Dormer BJ Jr, Babbett JA: Root section in the submaxillary space. *Oral Surg Oral Med Oral Pathol* 35:876, 1973.
6. Hutchinson D: An unusual case of lingual displacement of a mandibular third molar root apex. *Oral Surg Oral Med Oral Pathol* 39:858, 1975.
7. Ho KH: Retrieval of a molar from the submandibular space—A case report. *Singapore Dent J* 5:61, 1980.
8. Pedlar J: Crown of a tooth in the lateral pharyngeal space. *Br Dent J* 161:335, 1986.
9. Mellor TK, Finch LD: Displaced third molar. *Oral Surg Oral Med Oral Pathol* 64:131, 1987.
10. Grandini SA, et al: Complications in exodontia—Accidental dislodgment to adjacent anatomical areas. *Braz Dent J* 3:103, 1993.
11. Gay-Escoda C et al.: Accidental displacement of a lower third molar.

- Report of a case in the lateral cervical position. *Oral Surg Oral Med Oral Pathol* 76:159, 1993.
12. Wang Z, Yang C: Removal of the residual roots fall into the floor of mouth and pterygomandibular space. *Shanghai Kou Qiang Yi Xu* 8:111, 1999.
  13. Esen E et al.: Accidental displacement of an impacted mandibular third molar into the lateral pharyngeal space. *J Oral Maxillofac Surg* 58:96, 2000.
  14. Pippi R, Perfetti G: Lingual displacement of an entire lower third molar. Report of a case with suggestions for prevention and management. *Minerva Stomatol* 51:263, 2002.
  15. Ertas U. et al: Accidental third molar displacement into the lateral pharyngeal space. *J Oral Maxillofac Surg* 60:1217, 2002.
  16. Koseglu BG et al: Lower third molar displaced in the sublingual space. *Dentomaxillofac Radiol* 31:393, 2002.
  17. Tumuluri V, Punnia-Moorthy A: Displacement of a mandibular third molar root fragment into the pterygomandibular space. *Aust Dent J* 47:68, 2002.
  18. Yeh, C.J., 2002. A simple retrieval technique for accidentally displaced mandibular third molars. *J. Oral Maxillofac. Surg.* 60, 836–837.
  19. Ozyuvaci H, Firat D, Tanyel C: Accidental displacement of a mandibular third molar: A case report. *Quintessence Int* 34: 278, 2003.
  20. Durmus E et al: Accidental displacement of impacted maxillary and mandibular third molars. *Quintessence Int* 35:375, 2004.
  21. De Biase A et al: Surgical removal of a left lower third molar root after iatrogenic displacement in soft tissue. Case report. *Minerva Stomatol* 54:389, 2005.
  22. Huang I Y et al: Surgical management of accidentally displaced mandibular third molar into the pterygomandibular space: A Case Report. *Kaohsiung J Med Sci* 2007;23:370–4
  23. Medeiros N and Gaffrée G: Accidental displacement of inferior third molar into the lateral pharyngeal space: case report. *J Oral Maxillofac Surg.* 2008 Mar;66(3):578-80
  24. Olusanya AA et al: Accidental displacement of mandibular third molar into soft tissue: a case report. *Afr J Med Med Sci.* 2008 Mar;37(1):77-80.
  25. Shahakbari R, et al: First report of accidental displacement of mandibular third molar into infratemporal space. *J Oral Maxillofac Surg.* 2011 May;69(5):1301-3.
  26. Arasa, L.A et al: 2012. Iatrogenic displacement of third molar roots into the sublingual space: report of 6 cases. *J. Oral Maxillofac. Surg.* 70, e107–e115.
  27. R. Anand R and Patil P.M: Accidental displacement of third molars; report of three cases, review of literature and treatment recommendations. *Oral Surgery* 6 (2013) 2–8.
  28. Kose I et al: Displaced lower third molar tooth into the submandibular space: Two case reports. *J Nat Sci Biol Med.* 2014 Jul-Dec; 5(2): 482–484.
  29. Silveira R J et al: Accidental Displacement of Third Molar into

- the Sublingual Space: a Case Report. J Oral Maxillofac Res 2014;5(3):e5.
30. Suer B T et al : Iatrogenic Displacement of Impacted Mandibular Third Molar into the Pterygomandibular Space: A Case Report. OHDM - Vol. 13 - No. 2 - June, 2014.
  31. Zhao S et al: Intraoral management of iatrogenically displaced lower third molar roots in the sublingual space: a report of 2 cases. Int J Clin Exp Med 2015;8(10):19591-19595.
  32. Vora M M , Nagargoje P N: Displacement of a mandibular Third molar in the Pterygomandibular space - a case report. JOADMS 2015;1(3):67-69.
  33. Solanki R, et al: Retrieval of mandibular third molar tooth accidentally displaced in submandibular space: Series of two cases. Indian J Dent 2016;7:105-8.
  34. Sisk AL, et al: Complications following removal of impacted third molars: the role of experience of the surgeon. Br J Oral Maxillofac Surg 1986;44:855-9.
  35. Bouloux GF, et al: Complications of third molar surgery. Oral Maxillofac Surg Clin North Am 2007;19:117-28.

**TABLES:**

**Table 1 Case Analysis From Literature Reviewed**

Study	C a s e n o	Fragment	Time interval	Space	complications	anesthesia	Surgical approach
Howe (1958) <sup>3</sup>	1	tooth	1 month	Submandibular	None	GA	Intraoral
Stacy and Orth (1964) <sup>4</sup>	1	root	1 day	Submandibular	None	GA	Extraoral
Dormer and Babett (1973) <sup>5</sup>	1	root	1 day	Submandibular	None	GA	Intraoral
Hutchinson (1975) <sup>6</sup>	1	root	immediate	Submandibular	None	GA	Intraoral
Ho (1980) <sup>7</sup>	1	tooth	1 year	Submandibular	None	GA	Intraoral
Pedlar (1986) <sup>8</sup>	1	crown	6 day	Lateral pharyngeal	abscess	GA twice	Tonsillectomy and remove (ENT)
Mellor and Finch (1987) <sup>9</sup>	1	tooth	2 years	Sublingual	None	LA	Intraoral cannot remove
Grandini et al (1993) <sup>10</sup>	2	Root Tooth	22days 3 years	Submandibular	Swelling, trismus; swallowing pain. Infection.	LA GA	Intraoral
Gay-Escoda et al (1993) <sup>11</sup>	1	tooth	16 monthes	Lateral cervical	Infection	GA	Extraoral
Wang and Yang (1999) <sup>12</sup>	1 1	root	1 week	Pterygo - Mandibular and submandibular	?	LA	Intraoral
Esen et al (2000) <sup>13</sup>	1	tooth	months	Lateral pharyngeal	Pain, swelling, trismus, abscess	GA	Tonsillectomy and remove (ENT)

Pippi and Perfetti (2002) <sup>14</sup>	1	tooth	3 days	Submandibular	None (mild swelling)	GA	Intraoral
Ertas et al (2002) <sup>15</sup>	1	tooth	immediate	Lateral pharyngeal	None	LA	Intraoral
Koseglu et al (2002) <sup>16</sup>	1	tooth	3 days	Sublingual	Pain and swelling	?	?
Tumuluri and Punnia Moorthy <sup>17</sup> (2002)	1	root	9 days	Pterygomandibular	Swelling, trismus	LA	Intraoral
Yeh (2002) <sup>18</sup>	3	1 tooth 2 root	?	Submandibular	?	LA and sedation	Intra- and extra orally
Ozyuvaci et Al (2003) <sup>19</sup>	1	tooth	2 days	Submandibular	Pain, swelling, trismus	GA	Intraoral
Durmus et al (2004) <sup>20</sup>	1	tooth	2 days	Submandibular	Trismus, slight swelling	LA	Intraoral
De Biase et Al (2005) <sup>21</sup>	1	tooth	3 days	Submandibular	None	LA	Intraoral
Huang et al (2007) <sup>22</sup>	1	tooth	2 monthes	pterygomandibular space	None	GA	Intraoral
Medeiros N, GaffréeG (2008) <sup>23</sup>	1	tooth	35 days	lateral pharyngeal	None	LA	Intraoral
OlusanyaAA AkadiriOA, Akinmoladu VI (2008) <sup>24</sup>	1	tooth	?	Submandibular	None	LA	Intraoral
ShahakbariR, Mortazavi H, EshghpourM (2011) <sup>25</sup>	1	tooth	20 days	infratemporal space	None	LA	Intraoral
Arasa et al. (2012) <sup>26</sup>	6	root	Immediately in 1 Delayed in 2	Sublingual	Fragment lost Lingual nerve injury Inferior alveolar nerve injury in one case	LA	Intraoral
Anand and Patil (2013) <sup>27</sup>	3	tooth	6 hours 1 month	Submandibular pterygomandibular space	None	GA LA	Intraoral
Jolly et al (2014) <sup>2</sup>	1	root	1 month	Submandibular	Trismus	LA	Intraoral
Kose et al (2014) <sup>28</sup>	2	Tooth Root	1 week	submandibular space	None	GA LA	Extraoral Intraoral
Silveira et al.(2014) <sup>29</sup>	1	tooth	21 days	Sublingual	None	LA	Intraoral
Suer et al (2014) <sup>30</sup>	1	tooth	2 years	pterygomandibular space	None	LA	Intraoral
Zhao et al (2015) <sup>31</sup>	2	root	?	Sublingual	None	LA	Intraoral
Vora and Nagargoje (2015) <sup>32</sup>	1	tooth	6 days	pterygomandibular space	None	GA	Intraoral
Solanki et al (2016) <sup>33</sup>	2	Root tooth	1 month 2 years	submandibular	None	LA	Extraoral Intraoral

Abbreviations: GA, general anesthesia; LA, local anesthesia; ?, no record.