

See discussions, stats, and author profiles for this publication at: <https://www.researchgate.net/publication/382254301>

Closure of Oroantral Fistula By Using Buccal Fat Pad or Buccal Advancement Flap: Comparative Study

Article · October 2016

DOI: 10.9790/0853-1510066771

CITATIONS

3

READS

50

3 authors, including:



[Hasan Ghanem](#)

Sorbonne University

5 PUBLICATIONS 23 CITATIONS

SEE PROFILE

Closure of Oroantral Fistula By Using Buccal Fat Pad or Buccal Advancement Flap: Comparative Study.

Ahmad Al Nashar¹, Hasan Ghanem², Bashar Ahmad³

¹(DDS, PhD student , Department of Oral and Maxillofacial Surgery, Faculty of Dentistry, Tishreen University , Syrian Arab Republic)

^{2,3} (Undergraduate Student, Faculty Of Dentistry, Al-Andalus University For Medical Sciences, Syrian Arab Republic)

Abstract: The aim of this study was to compare the clinical outcomes of buccal fat pad flap or buccal advancement flap in closure of the oroantral fistula. A total of 20 patients with oroantral fistulae were selected for this study. Ten patients were treated with Buccal Advancement Flaps (BAFs) (Group1), and 10 were treated with buccal Fat pad flaps(BFPFS) (Group2). The parameters evaluated included, closure of the fistula, pain, swelling, maximum mouth opening, and vestibular depth. Assessments for clinical parameters were made on the day of surgery, on days (2 and 7) and 3 months. All fistulae were successfully closed in BFPF group at the end of the third month, the success rate was 100% and it was 80 % in BAF group. Statistically significant differences were detected for the swelling and trismus values between the two treatment groups on the second postoperative day). The mean of vestibular depth were 8.20 ± 2.48 in BAF group and 12.10 ± 0.99 in BFPF group with statistically significant differences. In spite of the immediate complications of the application of the buccal fat pad in closing the oroantral fistulae, it could be considered safe and reliable Procedure comparing with Buccal advancement flap.

Keywords: Buccal advancement flap, Oroantral fistula, pedicled buccal fat pad graft

I. Introduction

Oroantral fistulae (OAF) are defined as pathological communications between the oral cavity and maxillary sinus lined by epithelium [1,2]. The primary reason is the anatomic proximity of the root apices to the sinus floor or projection of the roots within the maxillary sinus [3]. If the OACs are left untreated and stay patent, 50% of the patients will experience sinusitis after 48 hours and 90% after 2 weeks in this case the OAC often persists and may become oroantral fistula (OAF) [4]. There are several alternative techniques to close oroantral fistulae, none of these methods are proved to be superior to the other. However, there are certain advantages and disadvantages of these methods [2,4,5]. The most common methods used today for closure of an OAFs are buccal and palatal flaps [5]. Disadvantages of this procedure include the obliteration of gingivolabial sulcus which makes it difficult to use prosthesis in future [4]. The BFP is an encapsulated, rounded, biconvex fatty structure located between the buccinator medially and the anterior margin of the masseter muscle, the mandibular ramus, zygomatic arch laterally [6]. It was first described by Egyedi, [7] as a pedicled graft covered with skin graft. Tideman et al, [7] reported on the idea of using the BFP as a pedicled graft and its complete epithelization without the use of skin graft for closure of oral defects. Then the buccal fat pad (BFP) has become popular for closing oronasal and oroantral communications and as a versatile pedicled graft for closing postsurgical maxillary defects [9-11]. However, during the past 3 decades, the BFP has become a well-established tool in oral and maxillofacial surgery for the closure of oroantral communications (OACs) [12]. The present study was conducted to compare the clinical outcomes of buccal fat pad flap or buccal advancement flap in closure of the oroantral fistula.

II. Materials And Methods

A total of 20 patients who were referred to Al andalus University, Faculty of Dentistry, Department of Oral Surgery with oroantral fistulae were selected for this study. Patients were excluded if there was signs of sinusitis and if the patients were above ASA2. Ten patients were treated with Buccal Advancement Flaps (BAFs)(Group1), and 10 were treated with buccal Fat pad flaps(BFPFS) (Group2), the patients were examined, and panoramic radiographs were taken to evaluate the size of the bone defect and presence of sinusitis or foreign material within the sinus.

1.1 Surgical Procedures:

Preoperatively, a panoramic radiographs were taken to ensure the healthy status of the maxillary sinus; the sinus was rinsed daily with saline solution for seven days (three times daily). All of the operations were performed under local anesthesia with 2% lidocaine and 1:80,000 adrenaline. A circular incision with a 3-mm margin was made around the fistula to excise completely the epithelial tract and inflammatory tissue within the

opening. In the BAF procedures, a broad-based trapezoid mucoperiosteal flap was created. After cleaning the fistula, the alveolar bone was smoothed, and the flap was advanced and sutured to the palatal tissue with silk suture material (3-0). For BFPFs procedures, The BFP was exposed by a 2-cm horizontal periosteal incision, lateral to the maxillary buttress, extending backward above the maxillary second molar tooth. Blunt dissection through the buccinators and loose surrounding fascia allowed the BFP to herniate into the mouth. The body of the BFP and the buccal extension were gently mobilized by blunt dissection, taking care not to disrupt the delicate capsule and vascular plexus and to preserve as wide a base as possible. Pressure on the cheek helped to express the fat into the mouth. After the pad had been dissected free from the surrounding tissues, it was grasped with vascular forceps, gently pulled out, advanced. Then the pad was passed through tunnel beneath palatal mucoperiosteal flap, came out and sutured to the mucosal edges of the incision at palatal side which made parallel to median line of hard palate Fig.1. All surgeries were performed by the same surgeon. After the operations, the patients were instructed to avoid activities that may produce pressure changes between the nasal passages and oral cavity for at least two weeks, such as sucking on a straw, blowing the nose, and sneezing with a closed mouth. The patients were placed on a specific diet during this period. Amoxicillin clavulanate 1 g twice daily, Ibuprofen 600 mg 3 × 1, and a nasal spray containing a vasoconstrictor 3 × 1 (2% ephedrine or 25% phenylephrine) and an antihistamine, such as pseudoephedrine 3 × 1 were prescribed for 1 week postoperatively. Sutures were removed 10 days after the surgery. The criterion for successful repair was complete healing of the flap without symptoms or signs of leakage.

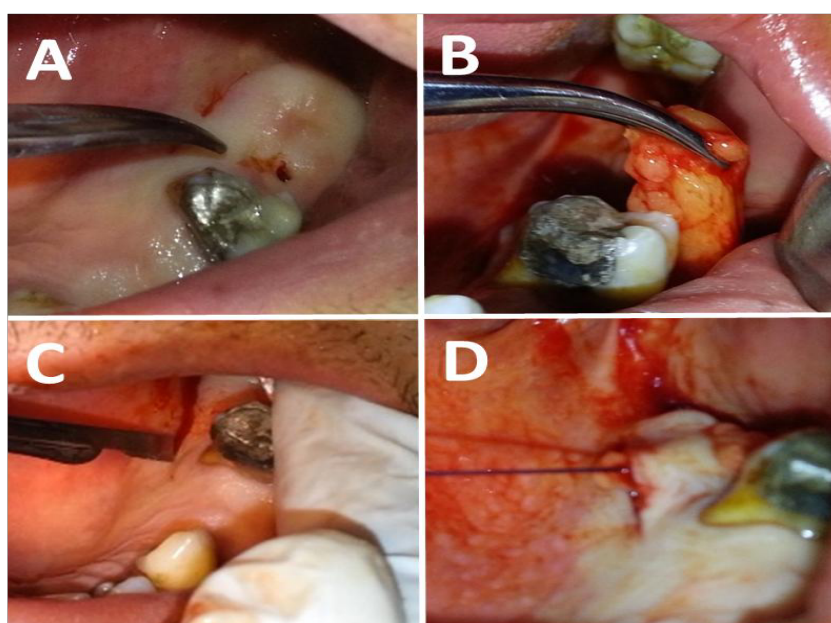


Figure 1

A: Preoperative view of fistula **B:** BFP after dissection
C: the palatal incision **D:** BFP through tunnel beneath palatal flap

2.2 Postoperative follow-up

Control appointments were made 1, 2, and 7 days and 3 months after the intervention Fig.2. During the first week, the vestibular depth, trismus, swelling, and pain intensity were assessed. The vestibular depth was measured with a compass as the distance between the marginal gingiva of the extraction site to the highest point in the vestibule in the same frontal plane. Pain intensity was assessed using a 10-point visual analogue scale (VAS), with the patient placing a mark on the scale to indicate an intensity range from no pain '0' to severe/unbearable pain '10'[13]. The severity of the pain was evaluated on the operation day and on postoperative days 2 and 7. The degree of facial swelling was determined by a modification[14] of the tape measure method described by Gabka and Matsumara [15]. Three measurements were made between five reference points: the distance between the lateral corner of the eye and angle of the mandible, the distance between the tragus and soft tissue pogonion, and the distance between the tragus and outer corner of the mouth. The mean of these three measurements was calculated. Measurements were taken pre-operatively and on postoperative days 2 and 7. Trismus was evaluated by measuring the distance between the edges of the upper and lower right central incisors at maximum opening of the jaws preoperatively and on days 2 and 7 after surgery.

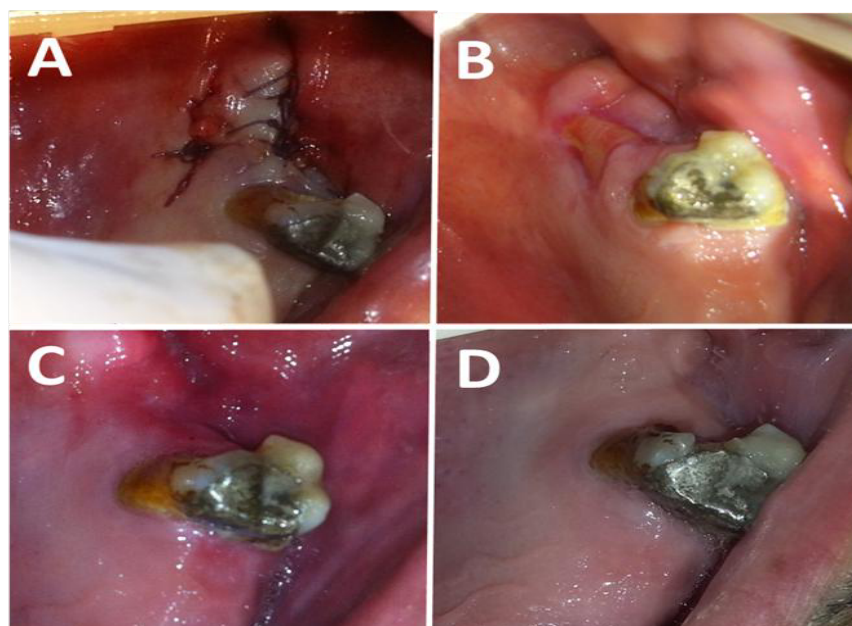


Figure 2

- A: immediately after surgery.
- B: View 2 weeks postoperatively.
- C: View 1 month postoperatively.
- D: View 3 month postoperatively

2.3 Statistical analysis

The statistical analyses were performed using SPSS version 17 software (SPSS Inc., Chicago, IL, USA). The ANOVA test was used to determine whether there was a statistical difference between groups in the parameters measured.

III. Results

Ten patients (six males , four females) with mean age 45.5 were treated with BAFs (Group1) , and 10 (five males ,five females) with mean age 46.3 were treated with BFPFS (Group2). The greatest incidence of OAF was found after extraction of the first molar, followed by extraction of the second molar. The second premolar were the involved teeth in one patient. The duration of the fistula in all the patients was longer than 1 month (range 1 month to 3 months) . All fistulae were successfully closed in BFPF group without symptoms or signs of leakage at the end of the third month. In BAF group, two patients were needed to another operation to close the fistulae . On the second postoperative day, facial swelling was significantly increased in BFPF group ($P = 0.006$) . By the seventh postoperative day, facial swelling in both groups was normal. (Table 1). Maximal mouth opening levels were similar preoperatively in the two groups. There was a significant decrease in mean maximal mouth opening in BFPF group on the second postoperative day compared to the preoperative measurement. The difference between the two groups was also statistically significant on the second postoperative day ($P = 0.033$). On the seventh postoperative day, almost all of the patients had regained their preoperative mouth opening (Table 2). With regard to the mean VAS scores, pain was highest on the operation and the second days and decreased gradually in both groups on postoperative day 7. There were no statistically significant differences in VAS scores between the two groups on the first and second postoperative day ($P = 0.288, 0.697$ respectively) (Table 3). The mean of vestibular depth before surgery were 13.40 ± 1.35 in BAF group and 13.00 ± 0.86 in BFPF group with no statistically significant differences ($P = 0.433$) . After surgery, the mean of vestibular depth were 8.20 ± 2.48 in BAF group and 12.10 ± 0.99 in BFPF group with statistically significant differences ($P = 0.000$) . (Table 4).

Table 1. Measurement of swelling (mean \pm SD in mm).

Groups	Preoperative	Second day	Seventh day
BAF	10.10 \pm 1.28	10.90 \pm 0.99	10.10 \pm 1.28
BFPF	10.00 \pm 0.81	12.40 \pm 1.17	10.20 \pm 0.91
P values	0.838	0.006	0.844

Table 2. Measurement of maximal mouth opening (mean \pm SD in mm).

Groups	Preoperative	Second day	Seventh day
BAF	39.20±5.05	38.00±5.35	38.70±4.62
BFPF	39.80±5.84	32.70±4.92	37.80±4.94
P values	0.872	0.033	0.386

Table 3. Comparison of VAS scores (mean ± SD).

Groups	Preoperative	Second day	Seventh day
BAF	4.40±0.84	3.10±1.19	0.60±0.84
BFPF	4.80±0.78	3.30±1.09	0.80±0.78
P values	0.288	0.697	0.591

Table 4. Measurement of the vestibular depth (mean ± SD in mm).

Groups	Preoperative	postoperative
BAF	13.40±1.35	8.20±2.48
BFPF	13.00±0.86	12.10±0.99
P values	0.433	0.000

IV. Discussion

The present study was conducted to evaluate the use of the pedicled buccal fat pad for the closure of oroantral fistulae. Oroantral fistula (OAF) most commonly occurs as a complication of maxillary molar or premolar extraction[16-19]. The highest incidence of OAFs in the present study was found after extraction of an upper first molar followed by the upper second molar, this is in accordance with other reports described by other authors. [2,16,20]. This can be explained on the higher frequency of extraction of these teeth and the divergence of their roots in addition to the difficulties in extraction of these . Buccal advancement flap which is also known as Rehrmann flap, is the common and oldest surgical technique used for the treatment of OAFs [21], it was used because of its reliability, versatility, ease of performance and better perfusion [2,20,22]. Its broad base ensures adequate blood supply and, consequently, high success rate had been reported [5]. In this study the success rate in BAF group was 80% which is similar to many studies in the past [2,3,5,16,23,24]. The success rate in BFPF group in present study was 100% . Dolanmaz et al, [25] have considered the pedicled BFP flap to be an acceptable and reliable alternative in management of acute or chronic oro-antral communication, and it seems to be the best choice of treatment, especially in recurrent oroantral fistulae. In their series of 75 cases, all of them had a favorable healing course after the operation, and the wounds became successfully epithelized in 3-4 weeks after surgery. The success rate in BFPF group was 100 % in Abuabara A et al, study [26] , they concluded that buccal fat pad seemed to be the best choices for treatment when a larger communication existed (>5 mm). Other authors also recommended the reconstruction of defects measuring under 5×4 cm without tension when using pedicled buccal fat pad [27,28]. The advantages of using BFPFs are: a quick and simple procedure, minimum failures rates, local anesthesia, no visible scars, low morbidity and no loss of sulcus depth [29,30]. The mean of vestibular depth after surgery in BAF group was 8.20±2.48 and 12.10±0.99 in BFPF group. Von Wovern, [31] considered that the narrowing in vestibular depth as a temporary complication, whereas Amaratunga, [32] reported it as a permanent complication of buccal advancement flap procedure. In accordance to another studies [29,30], Our findings demonstrated that facial swelling and trismus are considered disadvantage of BFPFs . Other complications has been described in the literature with BFPFs such as infection, necrosis and partial rupture of the flap[6,12]. In this study partial necrosis of the flap was observed in two patients but this did not affect the final healing. According to Hanazawa et al , when fat tissue is exposed to the oral environment, it becomes epithelialized and it is gradually replaced by fibrous conjunctive tissue within a 30-40-day postoperative period, without any functional damage to the treated site[18].

V. Conclusion

In spite of the immediate complications of the application of the buccal fat pad in closing the oroantral fistulae, it could be considered safe and reliable procedure comparing with buccal advancement flap.

References

- [1]. RC. Meirelles, RM. Naves-Pinto, Oroantral fistula and genian mucosal flap : a review of 25 cases, Rev Bras Otorrinolaringol, 74(1), 2008, 85-90.
- [2]. T. Yilmaz, AE. Suslu, B. Gursel, Treatment of Oroantral Fistula: Experience With 27 Cases, American Journal of Otolaryngology, 24(4),2003, 221-3
- [3]. O Guven, A clinical study on oroantral fistulae, J Craniomaxillofac Surg,26,1998, 267-71.
- [4]. Dym H, Wolf JC, Oroantral communication, Oral and maxillofacial surgery clinics of North America, 24(2), 2012,239-47.
- [5]. SH. Visscher, B. van Minnen, RR. Bos, Closure of oroantral communications: a review of the literature, Journal of oral and maxillofacial surgery, 68(6), 2010,1384-91.
- [6]. H-M. Zhang, Y-P. Yan, K-M. Qi, J-Q. Wang, Z-F. Liu, Anatomical structure of the buccal fat pad and its clinical adaptations, Plastic and reconstructive surgery,109(7), 2002,2509-20.

Closure of Oroantral Fistula By Using Buccal Fat Pad or Buccal Advancement Flap...

- [7]. P. Egyedi, Utilization of the buccal fat pad for closure of oro-antral and/or oro-nasal communications, *Journal of maxillofacial surgery*, 5,1977, 241-4.
- [8]. H. Tideman, A. Bosanquet, J. Scott, Use of the buccal fat pad as a pedicled graft, *Journal of Oral and Maxillofacial Surgery*,44(6),1986,435-40.
- [9]. EJ. de Moraes, Closure of oroantral communication with buccal fat pad flap in zygomatic implant surgery: a case report, *International Journal of Oral & Maxillofacial Implants*, 23(1), 2008,143-6.
- [10]. M. Allais, PE. Maurette, ALV. Cortez, JR. Laureano Filho, R. Mazzonetto, The buccal fat pad graft in the closure of oroantral communication, *Revista Brasileira de Otorrinolaringologia*, 74(5), 2008,799.
- [11]. P. Scott, G. Fabbroni, DA. Mitchell, The buccal fat pad in the closure of oro-antral communications: an illustrated guide, *Dent Update*, 31, 2004,363-6.
- [12]. PW. Poeschl, A. Baumann, G. Russmueller, E. Poeschl, C. Klug, R. Ewers. Closure of oroantral communications with Bichat's buccal fat pad, *J Oral Maxillofac Surg*, 67, 2009,1460-6.
- [13]. WI, Campbell, S. Lewis. Visual analogue measurement of pain, *Ulster Med J*, 59, 1990,149e54.
- [14]. S. Schultze-Mosgau, R. Schmelzeisen, Frolich, H. Schmele, Use of ibuprofen and methylprednisolone for the prevention of pain and swelling after removal of impacted third molars, *J Oral Maxillofac Surg*, 53,1995,2-7.
- [15]. J. Gabka, T. Matsumara. Measuring techniques and clinical testing of an anti-inflammatory agent (tantum), *Munch Med Wochenschr*, 113, 1971,198-203.
- [16]. HC. Killey, LW. Kay, An analysis of 250 cases of oro-antral fistula treated by the buccal flap operation, *Oral Surg Oral Med Oral Pathol*, 24, 19677, 26-39.
- [17]. J. Punwutikorn, A. Waikakul, V. Pairuchveg, Clinically significant oroantral communications: a study of incidence and site, *Int J Oral Maxillofac Surg*, 23, 1994,19-21.
- [18]. Y. Hanazawa, K. Itoh, T. Mabashi, K. Sato, Closure of oroantral communications using a pedicled buccal fat pad graft, *J Oral Maxillofac Surg*, 53,1995,771-5.
- [19]. O. Guven, A clinical study on oroantral fistulae, *J Craniomaxillofac Surg*, 26, 1998, 267-71.
- [20]. J. Hernando, L. Gallego, P. Villarreal, oroantral communications , A retrospective analysis, *Med Oral Pato Oral Cir Bucal* , 15, 2010,499.
- [21]. A. Rehrmann, A method of closure of oroantral perforation, *Dtsch Zahnarzt Z*, 39, 1936,1136-9.
- [22]. MS. Elarbi, The management of an oroantral fistula-a clinical study of 30 cases, *Pak Oral Dent J*, 26, 2006, 55-58.
- [23]. K. Sokler, V. Vuksan, T. Lauc, Treatment of oroantral fistula, *Acta Stomatol Croat*, 36,2002, 135-40.
- [24]. R. Haas, G. Watzak, M. Baron, G. Teppe, G. Maliath, G. Watzek, A preliminary study of monocortical bone grafts for oroantral fistula closure, *Oral Surg Oral Med Oral Pathol Oral Radiol Endod*, 96, 2003, 263-66.
- [25]. D. Dolanmaz, H. Tuz, S. Bayraktar, M. Metin, E. Erdem, T. Baykul, Use of pedicled buccal fat pad in the closure of oroantral communication: analysis of 75 cases, *Quintessence international*, 35(3), 2004, 241-6.
- [26]. A. Abuabara, AL. Cortez, LA. Passeri, M. Moraes, RW. Moreira, Evaluation of different treatments for oroantral/oronasal communications: experience of 112 cases, *Int J Oral Maxillofac Surg*, 35, 2006, 155-58.
- [27]. J. Singh, K. Prasad, RM. Lalitha, K. Ranganath, Buccal pad of fat and its applications in oral and maxillofacial surgery: a review of published literature (February) 2004 to (July) 2009, *Oral Surg Oral Med Oral Pathol Oral Radiol Endod*,110, 2010, 698-705.
- [28]. ES. Kim, Clinical evaluation of the effectiveness of pedicled buccal fat pad grafts in closure of oroantral communications, *J Korean Assoc Oral Maxillofac Surg*, 26, 2000, 297-300.
- [29]. FL. Pereira, GJ. Farah, LG. Passeri, AJ. Pavan. Aplicação do Corpo Adiposo Bucal para o Encerramento de fistula Bucosinusal. Relato de Caso, *Rev Port Estomatol Cir Maxillofac*,45, 2004,221-6.
- [30]. AD. Rapidis, CA. Alexandridis, E. Eleftheriadis, AP. Angelopoulos, The use of the buccal fat pad for reconstruction of oral defects: review of the literature and report of 15 cases, *J Oral Maxillofac Surg*,58, 2000,158-63
- [31]. N, Von Wovern. Closure of oroantral fistula with buccal flap: Rehrmann versus Moczar, *Int J Oral Surg*, 11,1982,156-59.
- [32]. NA, Amaratunga, Oroantral fistula: a study of clinical, radiological and treatment aspects, *Br J Oral Maxillofac Surg*, 24, 1986,433-37.